

# UNPLANNED EXTUBATION

---

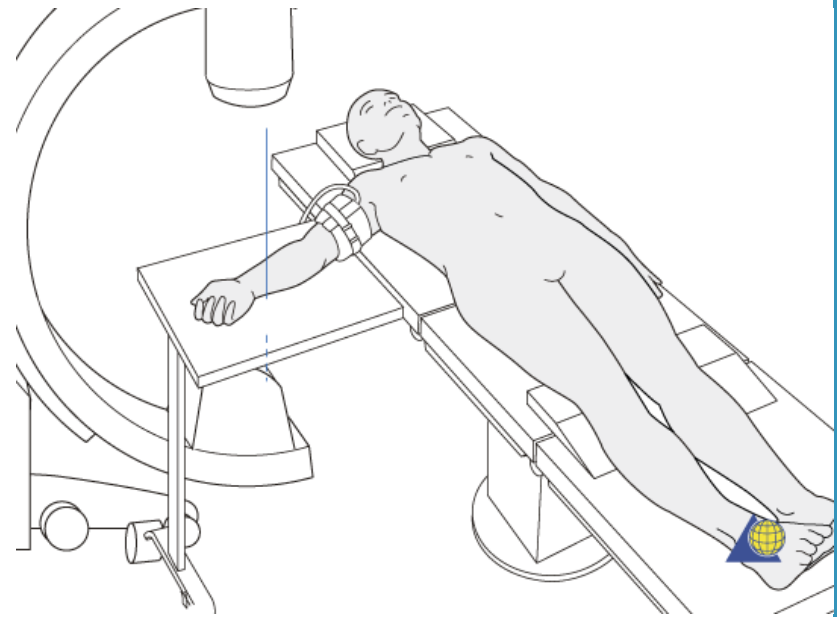
Jessica Muchmore, Trust grade, Torbay Hospital

# Overview

- Report of a loss of airway on the table
- Descriptions of methods to secure airways
- Learning points

# 4yr old boy undergoing wiring of supracondylar fracture of R arm

- Took over case at 1800hrs to relieve day team
- Anaesthesia already established
  - A: Grade 1 view, size 5 uncuffed ETT taped at 16cm
  - B: IPPV maintaining sats 98% FiO2 0.5 on volatiles
  - C: Nil of note
  - D: MAC 1.4
  - E: Positioned supine with R arm on arm board and head ring under occiput and entirely covered by drapes



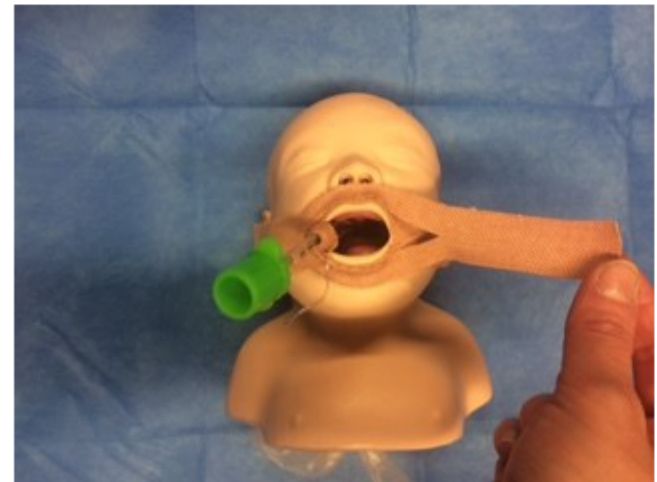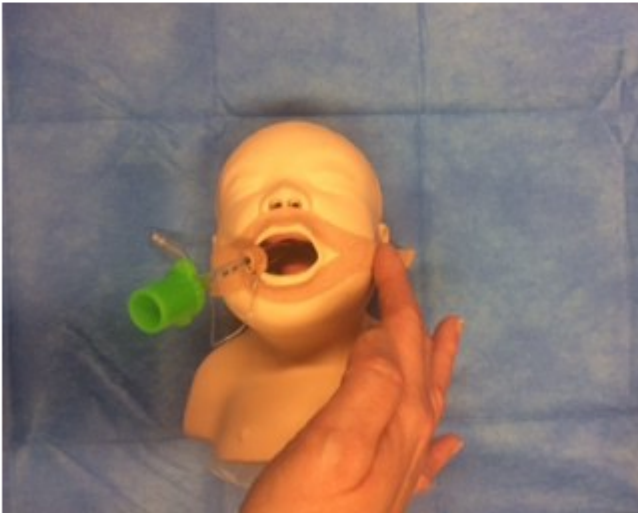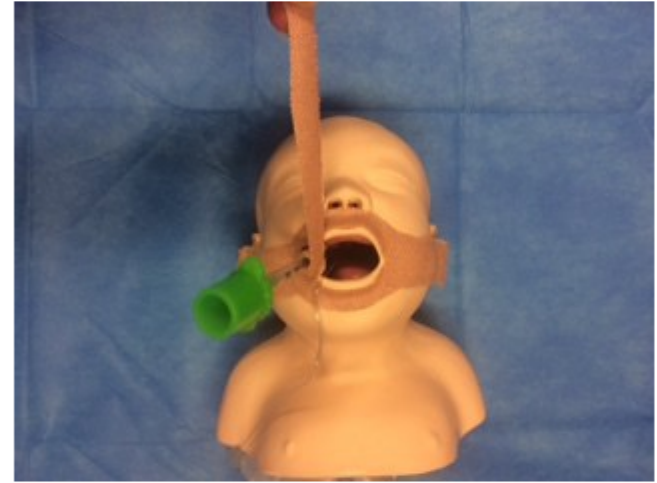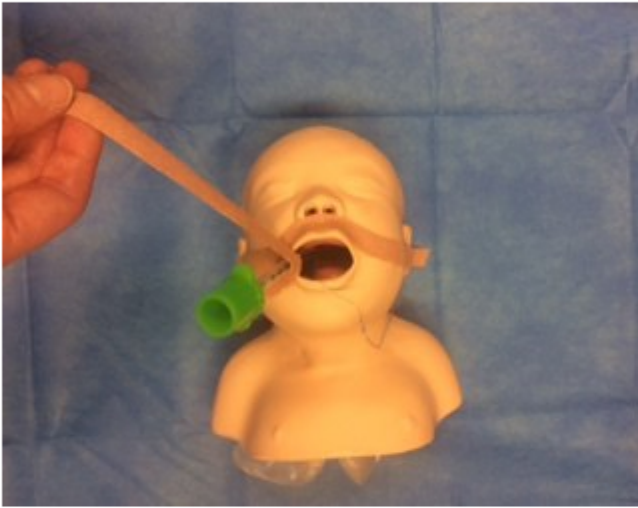# “I can hear snoring...”

- Stopped surgery
- Brought up onto bed, FM ventilation
- Called for senior help
- Sats to 80% at lowest
- Re-paralysed and reintubated
- Continued with surgery

# Unplanned extubation

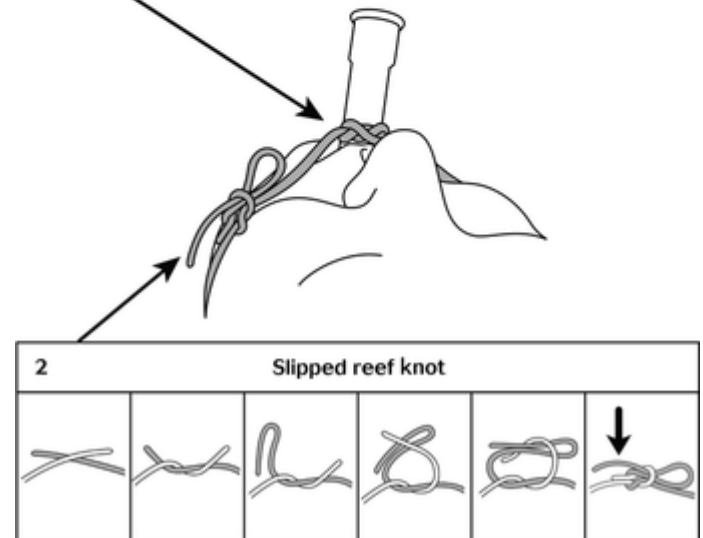
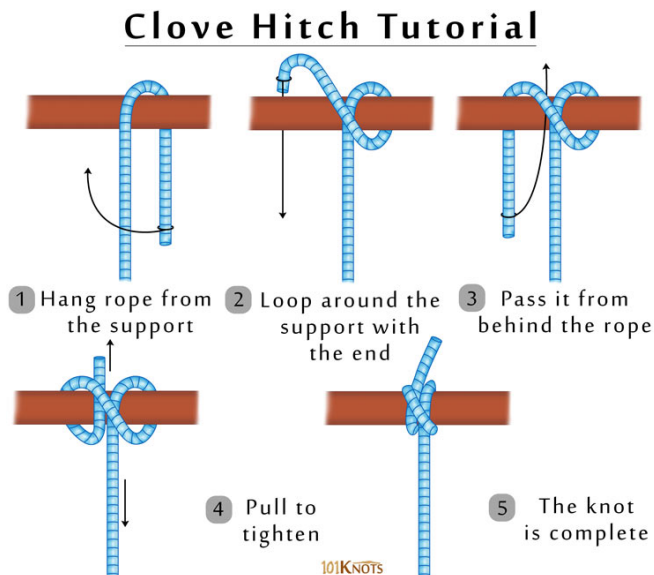
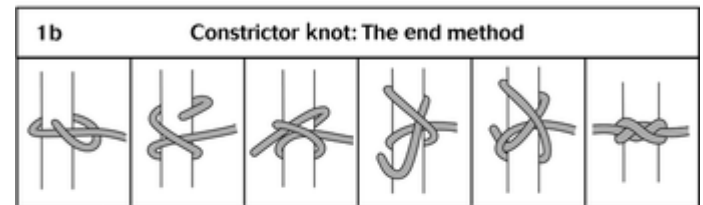

- Occurs in 3-16% of pts on IPPV (including ICU)
- Is associated with:
  - Trauma
  - Laryngospasm
  - Bronchospasm
  - Hypoxia
  - Awareness

# Securing ET tubes - TAPE



# Securing ET tubes - TIES

- Non-slip knot around tube
  - Clove hitch
  - Constrictor knot
- Quick release knot around neck



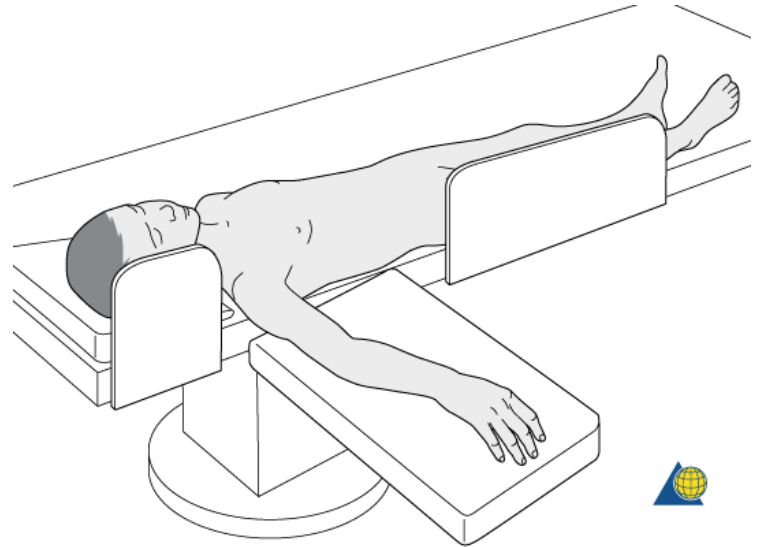
# Alternatives

- ET tube holders – primarily ICU and prehospital setting
- Secured to teeth
- Bridled
- Head wraps
- Many other inventions documented in case reports!



# Learning points

- Check positioning of patients airway when assuming responsibility for a case
- Position patients at edge of table with side supports either side of arm board
- Set TV alarms
- Secure drapes out of the way
- Appropriate tapes/ties applied correctly



Any questions or comments?